

# The problem of lice reinfestation in a 4-year old boy – a case study

Barbara Butwin<sup>1,A</sup>, Jolanta Wesolowska<sup>2,B</sup>✉, Agnieszka Kaczmarek<sup>2,C</sup>, Antonina Wawrzecka<sup>2</sup>, Justyna Wojnarowicz<sup>2,D</sup>, Ewa Duchnik<sup>2,E</sup>

<sup>1</sup> Dermasens Barbara Butwin, Wroclawska 36, 40-217 Katowice, Poland

<sup>2</sup> Pomeranian Medical University in Szczecin, Department of Aesthetic Dermatology, Powstańców Wlkp. 72, 70-111 Szczecin, Poland

<sup>A</sup> ORCID: 0000-0003-1295-9334; <sup>B</sup> ORCID: 0000-0003-0200-5510; <sup>C</sup> ORCID: 0009-0009-5847-9222; <sup>D</sup> ORCID: 0000-0003-1103-5236; <sup>E</sup> ORCID: 0000-0003-3855-7595

✉ jolanta.wesolowska@pum.edu.pl

## ABSTRACT

**Introduction:** Pediculosis is a parasitic disease that can spread among children but it can also affect adults. It is not necessarily the result of neglected or poor hygiene. Infection with head lice can occur not only in large clusters of children but also in salons providing cosmetic or hairdressing services. Despite easy access to various pharmacological agents, pediculosis can be a challenging problem to combat.

**Case report:** The paper presents a case of a 4-year-old boy in whom the methods of eliminating lice, used independently by his

mother at home, ended in failure each time. The family turned to a trichologist for help.

**Conclusions:** Supporting the diagnosis with the use of a micro-camera can eliminate misdiagnosed cases of head lice in the presence of dandruff, scabs, or various types of scalp impurities. This will be important in preventing the unnecessary implementation of treatment, which may change the resistance patterns of lice to agents generally available in pharmacies, thus affecting the effectiveness of head lice treatment.

**Keywords:** head lice; infestation; permethrin.

## INTRODUCTION

Head lice infestation (head pediculosis), one of the oldest diseases to affect humans and one of the most widespread parasitic diseases, is nowadays regarded as an embarrassing condition. Contrary to the prevailing belief, it is not solely a problem for individuals with poor personal hygiene [1, 2]. Although generally not associated with serious complications, head pediculosis is a disease that does not typically necessitate hospitalization or medical leave until the parasites are completely removed from the hair and scalp. In Poland, head pediculosis is not classified as an infectious disease under the Act of 5 December 2008 on preventing and combating infections and infectious diseases in humans (Journal of Laws of 2013, item 947, as amended); rather, it is recognized as a parasitic disease [3].

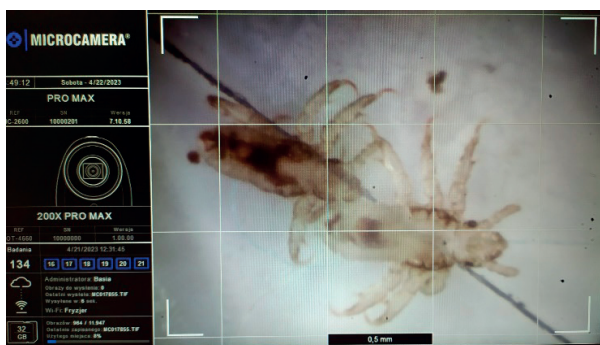The occurrence of head lice cases does not compel the State Sanitary Inspection to include them in anti-epidemic efforts to combat or prevent infections and infectious diseases. The notion that easy access to pharmacological agents in pharmacies that eliminate lice infestations provides effective protection against infection seems incorrect. This is supported by the fact that pediculosis remains a significant and recurring problem among families with preschool and school-age children, as well as in adults. Families are not always equipped to handle this issue on their own [4]. In Poland, commonly used agents containing cyclomethicone, permethrin, dimethicone, jojoba wax, coconut oil, and alcohol are employed to combat pediculosis. The primary treatment for scalp infestation is 1% permethrin, which shows the least toxic effect in humans but can lead to side effects such as skin itching, erythema, and swelling [2, 5]. In addition to 1% permethrin, dimethicone, and cyclomethicone are also used in

Poland. The substances cover lice and nits, blocking their respiratory systems and disrupting water management, thereby drying out parasite eggs [6, 7]. Oils, through their occlusive action, physically obstruct the lice's respiratory system openings [8]. On the contrary, benzyl alcohol causes lice to suffocate but lacks an ovicidal effect. Furthermore, it can induce itching, erythema, and eye mucosa irritation [9].

The duration of the head lice development cycle is crucial for treatment and reinfestation considerations. By assessing the distance between empty nits (hatched lice eggs), it is possible to determine the time since the onset of infection [10]. After fertilization, female lice lay about 7–10 eggs, attaching them at the base of human hair. Eggs must be situated very close to the scalp to ensure proper incubation conditions involving heat and moisture. Common egg-laying sites include the occipital region, periauricular area, and frontal area (along the hairline), particularly in girls with bangs [7]. Nymphs hatch from eggs within 6–10 days, representing a juvenile form that lives on the skin and feeds on the host's blood. After roughly 7–10 days and undergoing 3 molting stages, hatched individuals mature into adults. Adult lice have a lifespan of about 20–30 days [5, 11].

Due to the specific structure of their limbs (Fig. 1), head lice are adapted to attach to hair shafts, although movement on smooth and slippery surfaces presents challenges for them. This ability to attach enables lice infestations to occur through contact with everyday objects. Parasites detached from hosts and without access to blood will perish within 48 h. Nits removed from environments where skin-emitted temperature provides optimal conditions for development will also die within a week. Head lice transmission most frequently occurs through head-to-head contact. The unique limb structure of

head lice (Fig. 1) allows them to attach to human hair. Smooth and slippery surfaces (plastic, metal, artificial leather) can hinder their movement [11]. Nonetheless, even on such surfaces, when in contact with a hairy head (e.g. on a hairdresser's chair, cosmetic chair, doctor's office couch, headrests on airplanes, cinemas, trains, buses, and cars), the parasite can instantly attach itself to the hair. The potential for lice transmission through shared combs, brushes, hairpins, toys, and through upholstered furniture or bed linen at home or in hospitality settings should not be underestimated. All types of fabrics used at home – including bedding, towels, and clothing – as well as treatment bedding in service centers, unless disposable (bedding, capes, undercoats, towels, etc.), should be washed at temperatures exceeding 60°C with the addition of agents such as Nitolic Wash. Adult lice can survive for several hours in cold, lukewarm, or warm water, while nits display even greater water resistance. Mishandling parasite infestation leads to rapid head lice spread and reinfestation.



**FIGURE 1.** Lice inhabiting a child's head. The characteristic prehensile legs (claws) at the limb endings facilitate lice attachment to the hair shaft. Image magnified 200X obtained with the PROMAX – MCHD CONNECTED lens. Source: Barbara Butwin, DERMASENS.PL

The antigen present in the saliva triggers inflammation, causing symptoms such as erythema, itching to papulo-bullous lesions, irritability, and possibly elevated body temperature. In cases of prolonged parasitic invasions, even iron deficiency anemia may develop [12].

## CASE REPORT

A woman with a 4-year-old male child came to the Dermasens trichology office. The boy experienced intense scalp itching due to head lice. The lice appeared on the child after visiting a hairdresser providing services for children. During the visit to the hairdressing salon, the child's mother observed that the hairdresser used the same cape for all clients (children), and the comb and scissors were not disinfected. Additionally, the hairdresser did not wash or disinfect her hands after finishing customer service. Some time after the described visit to the hair salon, the woman noticed lice and nits on the child's head. She immediately went to the pharmacy, where she bought the appropriate treatment (Sora forte) and, following the instructions given by the pharmacist, carried out the parasite elimination process. However, 2 weeks after the entire procedure, the

child developed intense itching of the scalp and tenderness of the frontal and parietal areas. The child also showed symptoms of irritability, woke up during sleep, and had a low-grade fever.

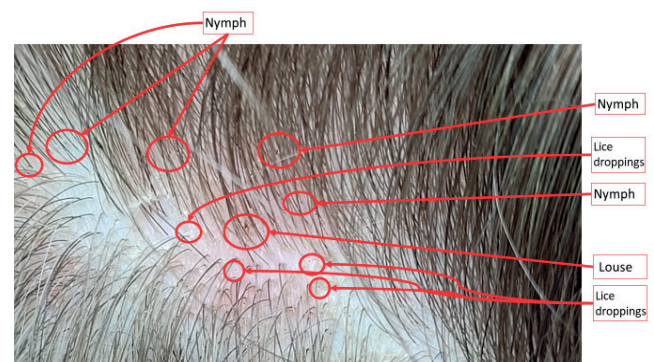
## OBJECTIVE

### Implementation of a procedure to prevent reinfestation of head lice in a 4-year-old child

A physical examination was performed using the MicroCAMERA HD PRO MAX CONNECTED, manufactured by APR Instruments s.r.l. Coccaglio (BS), Italy. The camera is equipped with a lens that magnifies the image by 200 times. The lens is additionally protected with glass to prevent the tested parasites from entering and infecting other patients/clients. The glass protecting the lens undergoes a decontamination procedure before each use. During the examination of the child, various impurities were observed. These included deposits in the form of black dots (lice excrement), red dots (microscopic blood drops left after a lice bite), numerous nits on the hair shafts at their roots (new nits) and at their ends (several days old nits ready to hatch) – Figures 2, 3. The child's head exhibited many nymphs actively seeking food. Furthermore, an erythematous area with intensive scaling of the epidermis and a characteristic odor were noticed in the parietal region of the head. Two young nymphal lice were also visible around this lesion (Fig. 3).



**FIGURE 2.** Nits attached to the hair of a 4-year-old child. Image captured with the PROMAX 200X – MCHD CONNECTED lens. Source: Barbara Butwin DERMASENS.PL



**FIGURE 3.** The scalp of a 4-year-old male child. Image captured with the 20X MCHD PROMAX CONNECTED lens. Notable nymphs, adult lice (along with their droppings), and in the central part scales previously lifted by combing. Skin erythema is visible in the lower right corner of the figure. Source: Barbara Butwin DERMASENS.PL

To execute an effective parasite elimination procedure for the child, an appointment was arranged for the late afternoon. During the home visit, the trichologist performed a thorough examination of all household members using the MicroCAMERA HD PRO MAX CONNECTED. First, the lice were eliminated, followed by the removal of nits from the hair shafts. The child was found to have over 150 nits on the hair shafts, 6 large lice, and approx. a dozen nymphs. The nits on the hair shafts were in varying growth stages, potentially leading to the emergence of new nymphs in the coming days. These nymphs would mature within a few days and become capable of laying eggs.

The procedure lasted more than 2 h. Due to the child's age, visible fatigue, the challenge of maintaining the head in a specific position, and the lateness of the hour, a decision was made to trim the hair to a length of approx. 2 mm. Subsequently, the child's head was thoroughly washed with SORA forte shampoo. After the hair was washed and dried, a considerable number of 0.5 mm nymphs were discovered on the scalp, particularly in the parietal area. This area exhibited erythema covered with scales and sebum. The remaining parasites were manually removed from the scalp and, together with the extracted hair and nits, were sealed in a securely closed bag and disposed of properly.

To prevent the reinfestation of head lice, the parents were provided with instructions on how to eliminate the parasites from household objects and surfaces, as well as from clothing, toys, and personal belongings. A follow-up visit was scheduled for 2 weeks later.

During the follow-up visit, the family underwent another examination with the MicroCAMERA H. Only the child's mother confirmed the presence of several nits in her hair. No live lice were detected. Some nits displayed evidence of complete thermal damage, and a few intact cocoons containing live individuals prepared to hatch were still observable. These cocoons were extracted and properly disposed of. The woman had been employing thermal hair straightener treatment daily, which resulted in damaging some nits. However, this treatment simultaneously aggravated the condition of the hair shafts and ends. As a resolution, the decision was made to cut the hair short and subject it to an intensive regenerative care routine.

## DISCUSSION

Head lice in the 4-year-old child probably appeared after a visit to a children's hair salon. Nits were also discovered in the child's mother, while the father remained free of lice or nits during examinations. This observation raises questions, since the father, like his wife (the child's mother), possesses long hair. It is possible that the father's practice of tying his long hair back smoothly or putting it in a bun hindered the easy transfer of lice. In addition, the father exhibited excessive sebum secretion on his scalp. Following hair washes, he noticed that his skin would be covered in sebum after an hour. This excess sebum production potentially serves as a deterrent for lice nesting and thriving on the skin. The composition of the sebum could also play a crucial role.

The family's independent efforts to combat head lice in the child, employing commonly available pharmacological treatments, proved ineffective, as reinfestations persisted. The process of eliminating the parasite in the child's hair spanned over 2 months. It is conceivable that more frequent application of the treatment might lead to a complete cure, but economic considerations within the family might pose an obstacle to continuing the prescribed course.

Traditional therapy with topical pediculicides is encountering increasing challenges due to the emergence of resistance to these treatments. Various factors could contribute to this resistance, including improper selection of the active ingredient, incorrect dosing, inadequate treatment duration, and, notably, inherent genetic resistance among lice. Consequently, it is pivotal to perform accurate diagnosis confirming the presence of lice, nits, or nymphs, followed by appropriate interventions [13].

Professional assistance from a trichologist, particularly utilizing diagnostic tools such as a micro-camera device, enabled a precise evaluation of the hair to detect nits and comprehensive examination of the scalp to eliminate nymphs – forms that are practically invisible to the naked eye. Parental self-examination of the scalp might prove insufficient, as they might misidentify nymphs as scalp impurities, mistaking them for particles like dust, sand, or dandruff.

Overlooking the existence of nymphs inevitably leads to the propagation of the infestation. Furthermore, when inspecting the scalp in educational institutions, daycare nurseries, or other child-oriented settings, or even at home by parents, the presence of dandruff, dust particles, sand, or so-called "pseudonits" (which can be idiopathic or secondary changes arising from seborrheic dermatitis, psoriasis, or compulsive hair pulling) could be mistaken for nits.

Initiating treatment with over-the-counter antiparasitic products without confirming the infestation's presence may lead to the development of resistant strains of parasites [14].

## CONCLUSIONS

1. There should be a strong emphasis on adhering to hygiene protocols within establishments that offer services to the public, especially in settings such as beauty salons, hairdressers, massage parlors, gyms, doctor's offices, hotels, trains, and airplanes. This includes practices like disinfecting headrest surfaces and completely replacing disposable pads. These measures are vital in preventing the infestation of head lice.

2. The utilization of micro-camera to support diagnosis:
  - can effectively eliminate cases where head lice are misdiagnosed due to the occurrence of dandruff, scabs, or various scalp impurities. This preventative approach is important in avoiding unnecessary treatments that might contribute to altering resistance patterns in commonly available treatments;
  - enables accurate diagnosis of infestations, thus preventing the reoccurrence of head lice infestations.

## REFERENCES

---

1. Fu YT, Yao C, Deng YP, Elsheikha HM, Shao R, Zhu XQ, et al. Human pediculosis, a global public health problem. *Infect Dis Poverty* 2022;11(1):58.
2. Clark JM. New chemistries for the control of human head lice, *Pediculus humanus capitis*: a mini-review. *Pestic Biochem Physiol* 2022;181:105013.
3. Obwieszczenie Marszałka Sejmu Rzeczypospolitej Polskiej z dnia 19 kwietnia 2013 r. w sprawie ogłoszenia jednolitego tekstu ustawy o zapobieganiu oraz zwalczaniu zakażeń i chorób zakaźnych u ludzi (Dz.U. z 2013 r., poz. 947).
4. Tytuła A, Jaształ-Kniażuk A, Błaszkiwicz PS, Kulbaka E, Bartosik K. Medyczno-społeczne i prawne aspekty opieki nad dzieckiem. *Probl Pielęg* 2018;26(3):171-6.
5. Nolt D, Moore S, Yan AC, Melnick L. Head lice. *Pediatrics* 2022;150(4):e2022059282.
6. Cummings C, Finlay JC, MacDonald NE. Head lice infestations: A clinical update. *Pediatr Child Health* 2018;23(1):e18-e24.
7. Meister L, Ochsendorf F. Head lice. Epidemiology, biology, diagnosis, and treatment. *Dtsch Arztebl Int* 2016;113(45):763-72.
8. Burgees IF. Physically acting treatments for head lice – can we still claim they are ‘resistance proof’? *Pharmaceutics* 2022;14(11):2430.
9. Frankowski BL, Bocchini JA. Wszawica skóry owłosionej głowy – raport kliniczny. *Dermatol Dypl* 2011;2(2):46-59.
10. Mehlhorn H. Head lice and their control: a never-ending story. In: Preedy VR, editor. *Handbook of hair in health and disease*. Wageningen: Wageningen Academic Publishers; 2012. p. 355-86.
11. Leung AKC, Lam JM, Leong KF, Barankin B, Hon KL. Paediatrics: how to manage pediculosis capitis. *Drugs Context* 2022;11:2021-11-3.
12. Sadhasivamohan A, Karthikeyan K, Palaniappan V. Pediculosis capitis with Id Reaction and plica polonica. *Am J Trop Med Hyg* 2021;105(4):862-3.
13. Fancelli C, Prato M, Montagnani C, Pierattelli M, Becherucci P, Chiappini E, et al. Survey assessment on pediatricians’ attitudes on head lice management. *Ital J Pediatr* 2013;39:62.
14. Rawat R, Mahajan VK. Peripilar keratin cysts or pseudonits: When nits are not nits! *Indian J Med Res* 2017;145(5):700.